

# Cost-effectiveness of portable Negative Pressure Wound Therapy (NPWT) over Split Thickness Skin Grafts (STSG) in the outpatient surgical setting compared to inpatient setting

Charles K. Lee, MD, FACS; Naomi De Tablan, DPM, Gina Restani, RN, Aliena Chin, RN & Barbie Mir, RN

## Introduction & Aim

NPWT plays an important role in reconstructive surgery to accelerate the healing process with Split Thickness Skin Grafts (STSG) in both inpatient and outpatient surgical settings. With rising healthcare costs and a growing need to decrease inpatient length of stay (LOS), we assessed the potential cost savings stemming from the use of a single-patient-use NPWT\* device over STSG in the post-surgical outpatient setting compared to the traditional 5-day inpatient stay after a STSG inpatient procedure. In this study, the portable single-patient-use NPWT\* treatment and work related costs were calculated as \$5617 USD average (range: \$3370 – \$6740) per treated patient, and all procedures were performed in the hospital surgical setting. Compared to standard wet-to-dry gauze dressings, the NPWT\* therapy provides an economic tool for lowering the total treatment time and costs.

## Methods

A portable single-patient-use NPWT device\* was applied in the operating room immediately post-operation on 3 patients (see Table 1 for the case series data). All the patients underwent debridement, thereafter split thickness skin grafts were applied. A silver contact layer was applied under the NPWT dressing on all patients. The NPWT dressing stayed in-situ for 5–12 days (9 days average). All patients were educated on the portable single-patient-use NPWT device\* and were discharged to home. All patients returned to the office for dressing removal.

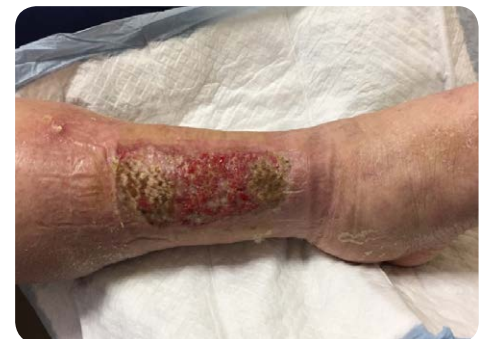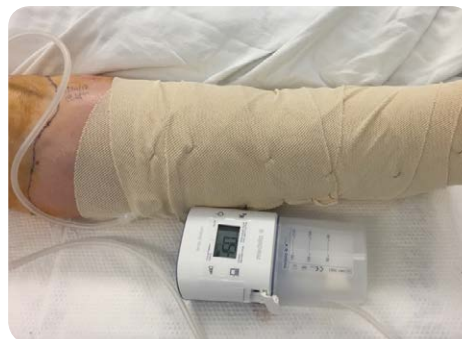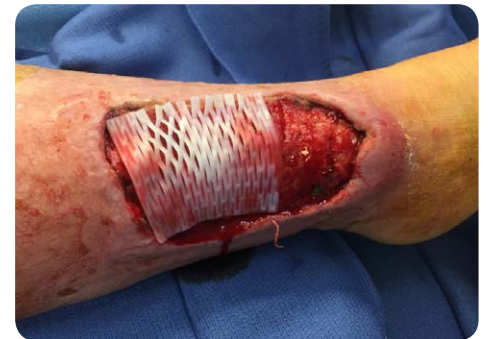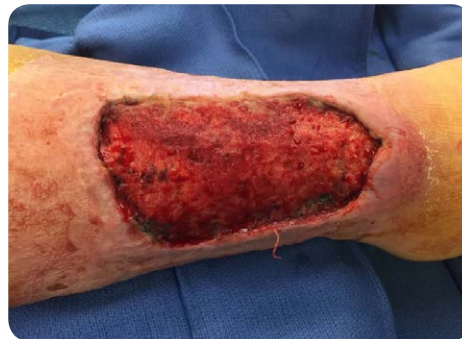## Patient Outcomes

We found that patients who underwent outpatients STSG procedures and who were started on a single-patient-use, portable NPWT\* were able to be discharged in 1–2 days, thereby reducing the need and associated costs of a lengthy hospital stay. Results from this 3 patient case series show significant financial savings as the minimum average cost for a 5-day inpatient stay is estimated to be \$16'850<sup>1</sup> (see Table 1. and Figure 2). The portable single-patient-use NPWT device\* was in place until the end of treatment. All dressing were removed in the surgeon's office and complete closure and healing was achieved (see photographs from Patient example JN).

## Patient example JN:

Diagnosis: Right leg complex open wound, infection and hematoma from blunt trauma.

Surgery: 02/01/2017 Right leg debridement and split thickness skin graft over Primatrix (dermal allograft), under NPWT\*.



## Patient JN

Dx: Right leg complex open wound, infection and hematoma from blunt trauma.

## Reference

<sup>1</sup> <http://hcupnet.ahrq.gov/HCUPTnet.jsp?id=28BC0B9F3A461490&Form=DispTab&JS=Y&Action=Accept>

**Table 1: Patient Data**

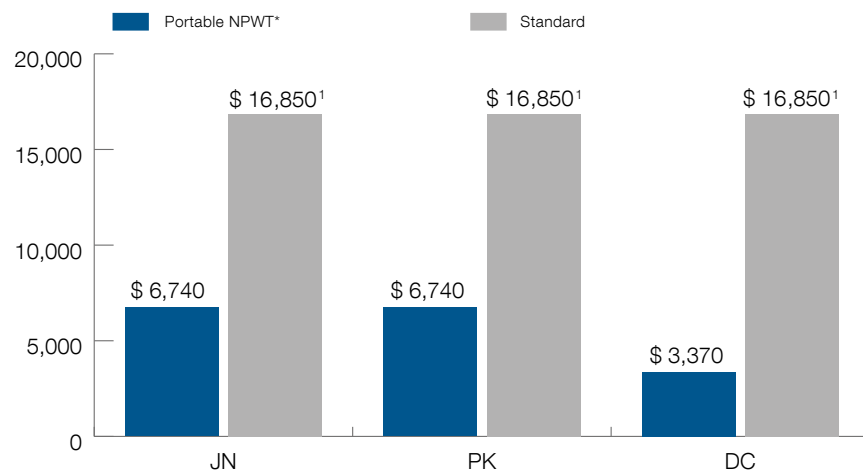
| Patient | Admission Date | Surgery Date | Discharge Date | Length of Stay (LOS) from Surgery to discharge | Time on NPWT | Estimated avg daily cost (Avg \$ 3370/ Day) | Standard LOS (Surgery to DC) | Standard daily inpatient surgical cost (Avg \$ 3370/ day) | Diagnosis  | Procedure  |
|---------|----------------|--------------|----------------|--|--------------|---|------------------------------|---|--|--|
| JN      | 1/31/2017      | 2/1/2017     | 2/22/17        | 2 days   | 12 days      | \$6'740                                     | 5 days                       | \$16'850 <sup>1</sup>                                     | Right leg complex open wound, infection hematoma from contusion of right leg | Right leg debridement and split thickness skin graft over Primatrix (dermal allograft), under NPWT.  |
| PK      | 1/6/2017       | 1/10/2017    | 1/12/2017      | 2 days   | 10 days      | \$6'740                                     | 5 days                       | \$16'850 <sup>1</sup>                                     | Left ankle complex open wound after previous total ankle joint replacement   | Left anterior tibial artery fasciocutaneous flap, full-thickness skin free graft, left leg   |
| DC      | 11/10/2016     | 11/15/2016   | 11/16/2016     | 1 day  | 5 days       | \$3'370                                     | 5 days                       | \$16'850 <sup>1</sup>                                     | Complex open scalp wound from head injury                                    | Local temporoparietal fasciocutaneous advancement flap, incision and drainage of hematoma in the subgaleal space, surgical preparation by excisional debridement of open wound, skin and subcutaneous tissue |

Average time with portable single-patient-use NPWT\*: 9 days

**Figure 2: Cost calculation for NPWT**

Treatment costs were calculated on the basis of USA private hospital prices in \$USD

Estimated Cost – Portable single-patient-use NPWT\* vs. Standard Protocol  
Sample: 3 patients – In '\$'



**CONCLUSION**

Collectively, we observed that this portable single-patient-use NPWT device\* can be used safely and effectively from the post-operative setting to the home setting. The mobility, reliability and ease of use of the device facilitated patient compliance. We were able to conclude that this portable single-patient-use NPWT device\* is clinically acceptable for several wound types in the post-acute setting. In this small case series, we found that the use of a single-patient-use, portable NPWT device for outpatient STSG procedures is more cost-effective than the inpatient alternative. Further research is needed to confirm the cost effectiveness of this portable single-patient-use NPWT device\* in the outpatient setting on patients with STSG.